

ERCP Tissue Sampling - Histoguide™ wire-guided forceps leads to conclusive diagnosis

Sang Kim, M.D.

Director of Interventional/Biliary Endoscopy
New York Presbyterian Hospital Queens, Flushing, NY



Procedures:

ERCP (endoscopic retrograde cholangiopancreatography) with biopsies of common hepatic duct stricture/mass and placement of biliary stent for relief of biliary obstruction.

Indications:

A 78-year-old male was admitted for abnormal LFTs (liver function tests) and an examination with CT revealed moderate intrahepatic biliary ductal dilatation. Tests showed distal common bile duct relative hyperattenuation, suspicious for sludge, cholangitis, or neoplasm. Also, gallbladder fossa hyperattenuation enhancing structure, which may represent an hyperenhancement of an irregular and contracted bladder. However, neoplasm could not be excluded.

MRCP (magnetic resonance cholangiopancreatography) revealed severe intrahepatic biliary dilatation and stricture at the biliary bifurcation. The middle and distal common bile duct was dilated up to 1.1cm. There was a 1.7cm soft tissue nodule at the biliary bifurcation which was suspicious for a Klatskin tumor.

Method 1:

First, ERCP was performed to obtain a diagnosis and pathology of the stricture/mass to determine treatment options such as surgery and/or chemotherapy. Biopsy with pediatric biopsy forceps (Boston Scientific), brushing with the Infinity® ERCP sampling device (US Endoscopy), and cholangioscopy with the SpyGlass DS System and the SpyBiteBiopsy Forceps (Boston Scientific) was conducted.

Results from Method 1:

Pathology from brushings performed with the Infinity® ERCP sampling device revealed atypical epithelial cells present in clusters. Pathology from the pediatric biopsy forceps revealed biliary mucosa/epithelium, negative for tumor. Pathology from the SpyBite Biopsy Forceps revealed atypical biliary epithelium, the differential diagnosis includes reactive atypia. Pathology from the first ERCP failed to make a definitive diagnosis of malignancy, although imaging studies, ERCP with the SpyGlass DS System and cholangioscopy all revealed a common hepatic duct stricture/mass. Directly visualized biopsies with the SpyBite Biopsy Forceps was unable to provide a diagnosis of malignancy.

continue to method 2 →

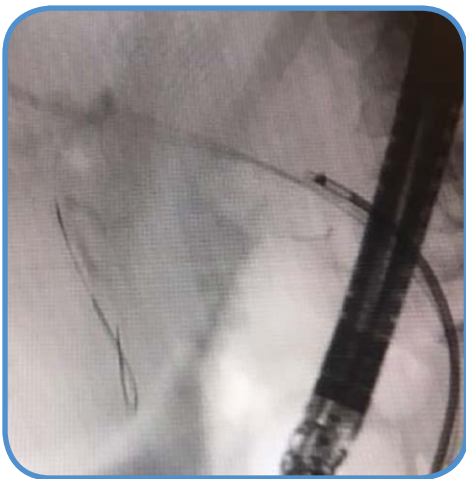
Method 2:

ERCP was repeated to obtain more tissue with via an alternate method, biopsies with the Histoguide™ wire-guided forceps.

Results from Method 2:

Pathology from the biopsies with the Histoguide™ wire-guided forceps revealed adenocarcinoma. Dysplasia of surface epithelium was present. The Histoguide™ wire-guided forceps was able to provide the diagnosis of malignancy for the patient, enabling proper therapy/chemotherapy for the patient.

Discussion:



Histoguide™ wire-guided forceps taking biopsy of stricture.

“The benefits of the Histoguide™ wire-guided forceps include ease of use as it can be performed simply over a wire. There is no SpyScope DS Access to setup and cholangioscopy to be performed followed by biopsies. Cholangioscopy and biopsies with the SpyBite Biopsy Forceps can be cumbersome and then to not acquire tissue is quite disheartening. Additionally, the cost of the SpyScope DS Access and the SpyBite Biopsy Forceps can be quite expensive.

The Histoguide™ wire-guided forceps is a simple biopsy forceps that is guided over the wire. In addition, the forceps are much larger than the SpyBite Biopsy Forceps and therefore able to obtain greater tissue samples. The Histoguide™ device was able to withstand the elevator and repeated “open/close” within the bile duct without becoming deformed or distorted and still function. Often, the standard or pediatric biopsy forceps is unable to open and close properly within the bile duct after a few passes, sometimes even after the initial/first pass. The Histoguide™ wire-guided forceps was also radiopaque and opening and closing of the jaw of the forceps could be clearly seen.”